

## Trigeminal neuralgia secondary to vascular compression and neurocysticercosis: illustrative case

Mao Vásquez, MD,<sup>1</sup> Luis J. Saavedra, MD,<sup>1</sup> Hector H. García, MD, PhD,<sup>2</sup> Evelyn Vela, MD,<sup>1</sup> Jorge E. Medina, MD,<sup>1</sup> Miguel Lozano, MD,<sup>1</sup> Carlos Hoyos, MD,<sup>1</sup> and William W. Lines-Aguilar, MD<sup>1</sup>

<sup>1</sup>Department of Neurosurgery, and <sup>2</sup>Cysticercosis Unit, National Institute of Neurological Sciences, Lima, Peru

**BACKGROUND** Trigeminal neuralgia (TN) is a frequent neurosurgical problem negatively influencing the quality of life of patients. The standard surgical treatment is microvascular decompression for primary cases and decompression of the mass effect, mainly tumors, for secondary cases.

Neurocysticercosis (NCC) in the cerebellopontine angle is a rare etiology of TN. The authors report a case in which NCC cysts around the trigeminal nerve coexisted with a vascular loop, which compressed the exit of the trigeminal nerve from the pons.

**OBSERVATIONS** A 78-year-old woman presented with a 3-year history of persistent severe pain in the left side of her face, refractory to medical treatment. On gadolinium-enhanced magnetic resonance imaging, cystic lesions were observed around the left trigeminal nerve and a vascular loop was also present and in contact with the nerve. A retrosigmoid approach for cyst excision plus microvascular decompression of the trigeminal nerve was successfully performed. There were no complications. The patient was discharged without facial pain.

**LESSONS** Albeit rare, TN secondary to NCC cysts should be considered in the differential diagnosis in NCC-endemic regions. In this case, the cause of the neuralgia was probably both problems, because when both were treated, the patient improved.

<https://thejns.org/doi/abs/10.3171/CASE23127>

**KEYWORDS** trigeminal neuralgia; microvascular compression; neurocysticercosis; retrosigmoid approach; Peru

Trigeminal neuralgia (TN) is the most common type of facial pain, negatively affecting quality of life and work capacity in 34% of patients.<sup>1</sup> TN has a prevalence of 4–13 cases per 100,000 inhabitants<sup>1–3</sup> and generally affects patients older than 50 years, with a female-to-male ratio of 1.5 to 1. In primary (classic) TN, compression by vascular loops is found at the entrance of the trigeminal nerve to the brainstem.<sup>4,5</sup> In secondary TN,<sup>6,7</sup> extrinsic compression of the trigeminal nerve triggers the pain. The most common causes of extrinsic TN are tumors (meningiomas, epidermoid cysts, acoustic neuromas, etc.) and, less frequently, aneurysms and arteriovenous malformations,<sup>5</sup> and rarer still, neurocysticercosis (NCC). In secondary TN, pathophysiological changes similar to those in primary TN occur, although the structural lesion depends on the etiology; for example, in multiple sclerosis, it is due to demyelination plaques.<sup>7</sup> The standard treatment for TN is microsurgical decompression of the trigeminal nerve. We present a case in

which neighboring NCC cysts, arachnoiditis, and vascular compression occurred in a patient with TN, who was treated with excision of the cysts plus microvascular decompression of the trigeminal nerve.

### Illustrative Case

#### History and Examination

A 78-year-old woman presented with intense pain and numbness in the left side of her face that felt like electric discharges and that started especially by chewing food, which prevented her from eating. Her only noticeable medical antecedent was arterial hypertension, which was under regular medical treatment. She was initially treated by the neurology department with anti-inflammatory drugs, analgesics, and carbamazepine (200 mg 3 times/day). As the pain was not controlled, she was referred for neurosurgical evaluation. On examination, there was a left V1–V2 facial hyposthesia and

**ABBREVIATIONS** AICA = anterior inferior cerebellar artery; CPA = cerebellopontine angle; MRI = magnetic resonance imaging; MS = multiple sclerosis; NCC = neurocysticercosis; TN = trigeminal neuralgia.

**INCLUDE WHEN CITING** Published May 22, 2023; DOI: 10.3171/CASE23127.

**SUBMITTED** March 9, 2023. **ACCEPTED** April 4, 2023.

© 2023 The authors, CC BY-NC-ND 4.0 (<http://creativecommons.org/licenses/by-nc-nd/4.0/>)

left sensorineural hearing loss and no other neurological sign. Gadolinium-enhanced magnetic resonance imaging (MRI) revealed cystic lesions in the left cerebellopontine angle (CPA), better seen on the fast imaging employing steady-state acquisition (FIESTA) sequence (Fig. 1). In addition, an elongated trigeminal nerve was observed trapped between two cystic lesions. The fluid-attenuated inversion recovery (FLAIR) sequence revealed pial edema around the pons, reflecting the inflammatory-immunological reaction of the parenchyma in response to the cysts. Toward the emergence of the trigeminal nerve, a branch of the anterior inferior cerebellar artery (AICA) was also seen in contact with the nerve. Immunodiagnosis using enzyme-linked immunoelectrotransfer blot (Western blot; sensitivity of 98% and specificity of 100% in patients with two or more viable brain lesions) and detection of circulating *Taenia solium* were both strongly positive. After evaluating the case, it was decided to use a retrosigmoid approach for the resection of the NCC cysts plus microvascular decompression of the left trigeminal nerve.

## Surgery

The surgical plan was, first, resection of the cysts and, later, exploration and possible decompression of the trigeminal nerve. The first surgery used a microsurgical retrosigmoid approach, with the patient in

the right lateral decubitus park-bench position with a 10-cm linear retroauricular incision at 4 cm from the ear posterior implant. Craniotomy was 4 cm in diameter, and the dura mater was opened, referencing the sigmoid sinus. Initially, the cerebrospinal fluid was drained to expand our work space. The cranial nerves VII–VIII complex was initially identified, and then the entire arachnoid of the CPA was observed with the thick, yellowish appearance typical of arachnoiditis secondary to NCC. After opening the arachnoids, the cystic lesions were visualized in the deeper plane (Fig. 2), again typical of NCC. NCC cysts are generally not attached to vascular structures or brain parenchyma, so saline irrigation and gentle traction were sufficient to remove the cysts. The cysts were extracted and the exploration was expanded. A branch of the AICA was found to be in contact with the base of the trigeminal nerve (Fig. 3). The artery was dissected from the arachnoid adhesions and separated from the nerve with a piece of Teflon. After hemostasis was verified, closure was performed in layers with the usual technique.

There were no complications during the procedure. The patient was extubated without added neurological signs and with relief from facial pain and was discharged 3 days later. Pathological examination of the excised membranes confirmed the diagnosis of NCC. Follow-up MRI at 2 months after surgery found no evidence of NCC cysts in the CPA (Fig. 4). She received antiparasitic treatment with albendazole, with concomitant steroids, for 2 months. Currently, the patient is under follow-up with a modified Rankin scale score of 0, without facial pain.

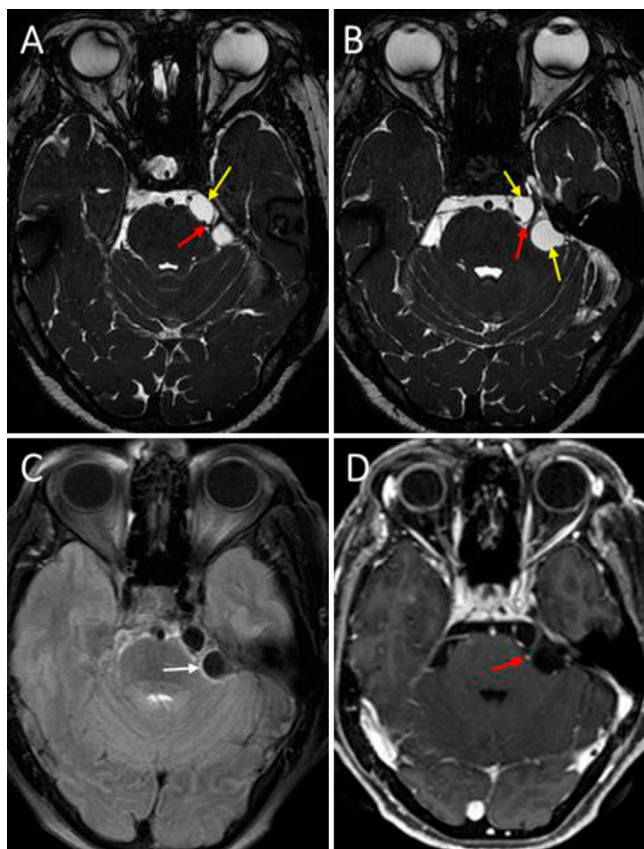
## Discussion

### Observations

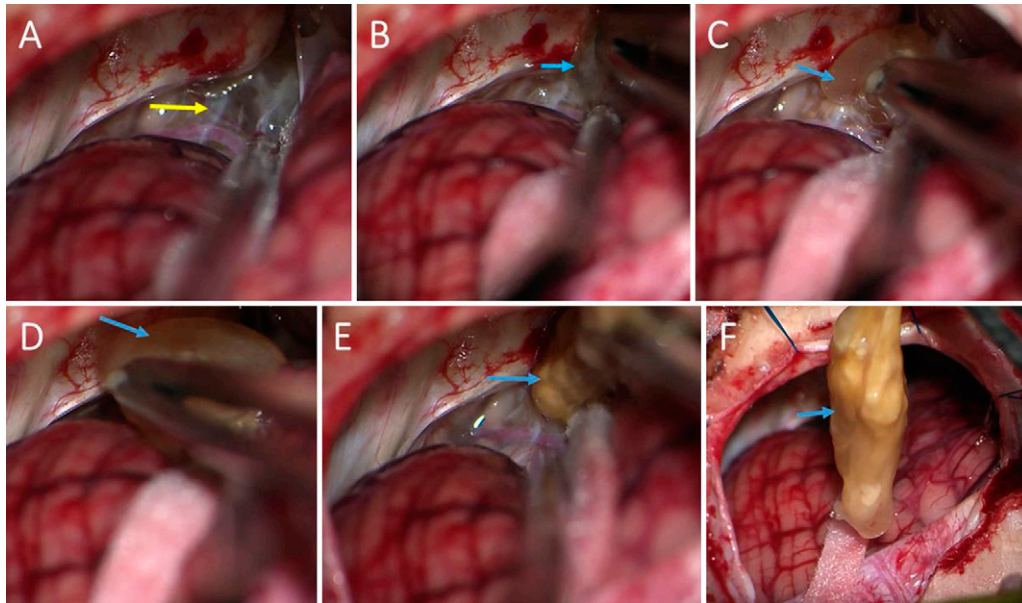
TN is a frequent and well-known neurosurgical problem significantly affecting the quality of life of patients. Its global incidence has remained constant, ranging from 12.6 to 27/100,000 inhabitants per year, which increases in people over 50 years and is slightly more frequent in women and on the right side.<sup>8,9</sup> Bilaterality can be seen in 5% of classic cases.<sup>10,11</sup> Undoubtedly, vascular compression is the most frequent cause. Of the secondary etiologies, multiple sclerosis (MS) is the most frequent cause of TN, with a prevalence ranging from 1% to 6.3%,<sup>12</sup> followed by intracranial tumors. Some cases secondary to NCC cysts or cysticercal arachnoiditis have also been reported. This immunological-inflammatory reaction can also generate irritation of other cranial nerves, such as the reported case of hemifacial spasm secondary to arachnoiditis due to NCC, which improved after release of the facial nerve.<sup>13</sup>

The diagnosis of TN remains fundamentally clinical.<sup>3,6,14</sup> The first-line treatment for TN continues to be anticonvulsant medical therapy, and those cases secondary to tumors or infectious inflammatory problems are treated initially with surgery.<sup>5,7</sup> In patients with MS, the prevalence is higher, and in addition to episodic pain, they often report a component of constant pain.<sup>10,12,15</sup> Although the pain is mainly unilateral in these patients, bilateral involvement can occur in up to 31% of TN cases secondary to MS.<sup>16</sup>

TN may also occur in patients with tumoral and/or infectious lesions of the CPA. While meningiomas (classically in the petrous apex) are the most frequently reported lesions associated with TN, small lesions in very specific locations can also cause it, as in the case reported by Ishi et al.<sup>17</sup> in 2015, in which a very small meningioma in the suprameatal tubercle, with hyperostosis at the entrance to Meckel's cave, led to intractable TN in a 72-year-old woman. Other frequent extra-axial tumors that may cause TN are acoustic



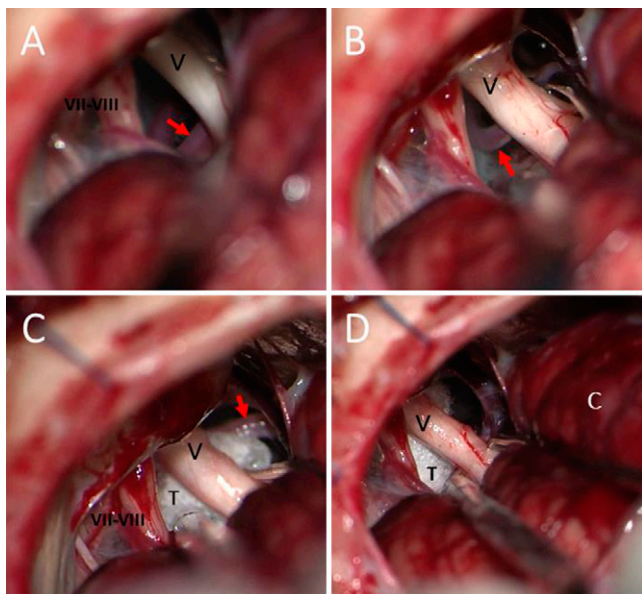
**FIG. 1.** Preoperative axial MRI. **A and B:** FIESTA sequences showing subarachnoid cystic lesions in the left cerebellopontine angle (*yellow arrows*) medial and lateral to the trigeminal nerve, which is elongated laterally. **C:** FLAIR sequence demonstrating hyperintensity (*white arrow*) in the pial plane of the pons around cysts. **D:** Gadolinium-enhanced, T1-weighted sequence showing a branch of the AICA at the exit of the trigeminal nerve from (*red arrows*).



**FIG. 2.** Intraoperative images, first stage. **A:** Initial view of the left cerebellopontine angle, with yellowish and thick arachnoids (yellow arrow). **B–F:** Identification and complete resection of NCC cysts (light blue arrows) around the trigeminal nerve.

neuromas or epidermoid tumors.<sup>18–20</sup> Rarer etiologies for TN have also been reported, such as in the patient who presented with TN as the only presenting symptom secondary to brain metastasis<sup>21</sup> or in association with Charcot-Marie-Tooth disease and bilateral TN, with only 4 reported cases.<sup>22</sup>

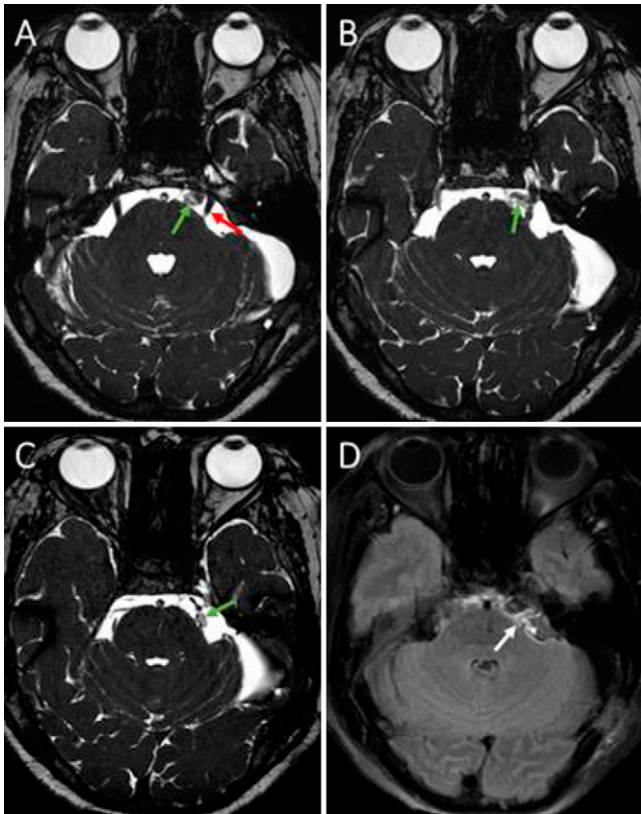
There are only a few reports of TN secondary to NCC. Tenuto et al.<sup>23</sup> reported two cases secondary to NCC cysts in Meckel's cave; one of the cases initially evaluated as clinical suspicion and the other as an intraoperative finding. Revuelta et al.<sup>24,25</sup> presented two cases—interestingly, one of them with contralateral neuralgia. This patient had NCC cysts in the left CPA with right-sided TN, and the pain completely subsided after removing the left cerebellopontine cysts. They suggested that the neuralgia was possibly caused by distortion of the brainstem resulting in compression of the nerve against an arterial loop at its entrance site. Their other case of NCC of the CPA with ipsilateral neuralgia was also alleviated after excision of the cysts. Hamamoto Filho et al.<sup>26</sup> reported another case secondary to ipsilateral NCC cysts in the CPA, in the absence of vascular compression. Aguiar et al.<sup>27</sup> reported another singular case—that is, a patient with bilateral TN with images of cystic lesions in the right CPA, which was finally reported as NCC, who also presented with neuralgia on the left side. The neuralgia improved on both sides after excision of the right CPA cyst. They considered that the neuralgia was caused by two probable mechanisms: a distortion of the brainstem and compression of the nerve against an arterial loop in the entry zone or arachnoiditis caused by NCC in both cisterns of the CPA. It is known that the inflammatory-immunological reaction produced by NCC cysts causes vascular damage in the form of vasculitis and nerve damage in the form of neuritis. The treatment does not conclude with the excision of associated cysts and may involve antiparasitic or anti-inflammatory regimens. Unlike the cases mentioned, in our case we observed both problems—that is, cysts and vascular compression.



**FIG. 3.** Intraoperative images, second stage. **A:** Initial view after extracting cysts, from the medial and lateral region of the trigeminal nerve (V), toward its exit point of the AICA pons branch (red arrow). **B:** After microsurgical dissection, the AICA branch of the trigeminal nerve is separated (red arrow). **C:** Placement of a piece of Teflon (T) between the vascular loop and the trigeminal nerve (red arrow). **D:** Final view of the trigeminal nerve free of any vascular compression or arachnoid adhesions. C = cerebellum.

### Lessons

NCC should be considered as a diagnosis in patients with cystic lesions in the CNS. In our case, in addition to the local inflammatory reaction, vascular compression could be observed, suggesting that both mechanisms contributed to the neuralgia. However, the exact



**FIG. 4.** Postoperative axial MRI. **A–C:** Axial FIESTA sequences showing the trigeminal nerve is now free of compression by the arterial loop (red arrow) and recovered its usual course, with Teflon fragments (green arrows) around it, and the absence of cystic lesions. **D:** In the FLAIR sequence, the pial pons hyperintensity (white arrow) persists.

role of each problem in the pathophysiology of neuralgia remains for analysis and discussion. Surgical resolution of both conditions resolved the patient's facial pain.

## References

- Alcántra Montero A, Sánchez Carnero CI. Update on the management of trigeminal neuralgia. Article in Spanish. 2016;42(4): 244–253.
- Tai AX, Nayar VV. Update on trigeminal neuralgia. *Curr Treat Options Neurol*. 2019;21(9):42.
- Bendersky M, Hem S, Landriel F, et al. Identifying the trigeminal nerve branches for transovale radiofrequency thermolesion: “no pain, no stress”. *Neurosurgery*. 2012;70(2 Suppl):259–263.
- Bescós A, Pascual V, Escosa-Bagé M, Málaga X. Treatment of trigeminal neuralgia: an update and future prospects of percutaneous techniques. Article in Spanish. *Rev Neurol*. 2015;61(3): 114–124.
- Araya EI, Claudino RF, Piovesan EJ, Chichorro JG. Trigeminal neuralgia: basic and clinical aspects. *Curr Neuropharmacol*. 2020; 18(2):109–119.
- Jannetta PJ, Rand RW. Transtentorial retrogasserian rhizotomy in trigeminal neuralgia by microneurosurgical technique. *Bull Los Angeles Neurol Soc*. 1966;31(3):93–99.
- Xu R, Xie ME, Jackson CM. Trigeminal neuralgia: current approaches and emerging interventions. *J Pain Res*. 2021;14: 3437–3463.
- Hall GC, Carroll D, McQuay HJ. Primary care incidence and treatment of four neuropathic pain conditions: a descriptive study, 2002–2005. *BMC Fam Pract*. 2008;9:26.
- Katusic S, Beard CM, Bergstralh E, Kurland LT. Incidence and clinical features of trigeminal neuralgia, Rochester, Minnesota, 1945–1984. *Ann Neurol*. 1990;27(1):89–95.
- Montano N, Conforti G, Di Bonaventura R, Meglio M, Fernandez E, Papacci F. Advances in diagnosis and treatment of trigeminal neuralgia. *Ther Clin Risk Manag*. 2015;11:289–299.
- Maarbjerg S, Gozalov A, Olesen J, Bendtsen L. Trigeminal neuralgia—a prospective systematic study of clinical characteristics in 158 patients. *Headache*. 2014;54(10):1574–1582.
- Putzki N, Pfriem A, Limmroth V, et al. Prevalence of migraine, tension-type headache and trigeminal neuralgia in multiple sclerosis. *Eur J Neurol*. 2009;16(2):262–267.
- Yang SY, Vásquez CM. Hemifacial spasm secondary to arachnoiditis due to neurocysticercosis: clinical image. *World Neurosurg*. 2020;143:180–182.
- Marín Medina DS, Gámez-Cárdenas M. Neuralgia del trigémino: aspectos clínicos y terapéuticos. *Acta Neurol Colomb*. 2019;35(4):193–203.
- Ruge D, Brochner R, Davis L. A study of the treatment of 637 patients with trigeminal neuralgia. *J Neurosurg*. 1958;15(5): 528–536.
- O'Connor AB, Schwid SR, Herrmann DN, Markman JD, Dworkin RH. Pain associated with multiple sclerosis: systematic review and proposed classification. *Pain*. 2008;137(1):96–111.
- Ishi Y, Asaoka K, Sugiyama T, et al. Case report: trigeminal neuralgia caused by a minute meningioma with hyperostosed suprameatal tubercle. *Case Rep Neurol*. 2015;7(2):167–172.
- Rahme R, Ali Y, Slaba S, Samaha E. Dural arteriovenous malformation: an unusual cause of trigeminal neuralgia. *Acta Neurochir (Wien)*. 2007;149(9):937–941.
- Niwant P, Motwani M, Naik S. Atypical trigeminal neuralgia secondary to meningioma. *Case Rep Dent*. 2015;2015:462569.
- Cirak B, Kiyimaz N, Arslanoglu A. Trigeminal neuralgia caused by intracranial epidermoid tumor: report of a case and review of the different therapeutic modalities. *Pain Physician*. 2004;7(1): 129–132.
- Shin JW, Oh E, Kim DH. Trigeminal neuralgia as a presenting symptom of brain metastasis in advanced stage of breast cancer. *J Neurol Sci*. 2019;405:44.
- Tekkok IH, Sumer M. Bilateral trigeminal neuralgia and Charcot-Marie-Tooth disease: diagnosis and successful microsurgical treatment of bilateral neurovascular compression. *Zentralbl Neurochir*. 2008;69(3):148–151.
- Tenuto RA, Canelas HM, Cruz OR, Franca LC. Trigeminal neuralgia caused by cysticercosis of the Cavum Meckelii: report of two cases. *J Neurosurg*. 1963;20:169–171.
- Revuelta R, Soto-Hernández JL, Vales LO, González RH. Cerebellopontine angle cysticercus and concurrent vascular compression in a case of trigeminal neuralgia. *Clin Neurol Neurosurg*. 2003;106 (1):19–22.
- Revuelta R, Juambelz P, Balderrama J, Teixeira F. Contralateral trigeminal neuralgia: a new clinical manifestation of neurocysticercosis: case report. *Neurosurgery*. 1995;37(1):138–139, discussion 139–140.
- Hamamoto Filho PT, Poliselis GB, Oliveira VA, et al. Unusual painful trigeminal neuropathy caused by racemose neurocysticercosis. *Pain Med*. 2016;17(5):992–994.
- Aguiar PH, Miura FK, Napoli PR, et al. Unusual cause for bilateral trigeminal neuralgia: unilateral racemose cysticercus of cerebellopontine angle. Case report. Article in Portuguese. *Arq Neuropsiquiatr*. 2000;58(4): 1138–1141.

**Disclosures**

The authors report no conflict of interest concerning the materials or methods used in this study or the findings specified in this paper.

**Author Contributions**

Conception and design: Lines-Aguilar, Vásquez. Acquisition of data: Lines-Aguilar, Vela, Hoyos. Analysis and interpretation of data: Lines-Aguilar, García, Medina. Drafting of the article: Lines-Aguilar, García. Critically revising the article: Lines-Aguilar, Saavedra, García.

Reviewed submitted version of the manuscript: Lines-Aguilar, García, Lozano. Approved the final version of the manuscript on behalf of all authors: Lines-Aguilar. Administrative/technical/material support: Lines-Aguilar. Study supervision: Lines-Aguilar. Operating surgeons: Lines-Aguilar, Vásquez.

**Correspondence**

William W. Lines-Aguilar: National Institute of Neurological Sciences, Lima, Peru. [williamincn@hotmail.com](mailto:williamincn@hotmail.com).